

HISTOPHYSIOLOGICAL FEATURES OF EPITHELIAL TISSUES

Ukrainian medical stomatological academy (Poltava)

olena.yakushko@gmail.com

Integration of Ukraine into the European higher education area requires the improvement of the existing organizational and functional educational model [0]. The competitiveness of the national system of medical education in the world market of educational services is evidenced by the quality of training of international students, especially the English-language form of instruction. In the conditions of increased demand of foreign citizens for medical education in Ukraine, the provision of optimal conditions and effective progressive methods of teaching and students' knowledge control is rational.

The Law of Ukraine "On Higher Education" (2014) emphasizes the lecture as one of the major types of training [0]. The scientific and methodical publications give the following definition of the lecture: "The tutorial lecture (Latin lectio – reading) is logically completed, scientifically substantiated, consistent and systematic presentation of a certain scientific or scientific-methodical issue, topic or section of the subject, enhanced, if necessary, by the visual aids and demonstration of experiments" [0].

The lecture is distinguished by its time effectiveness, the ability to accumulate and provide students with a large amount of academic and scientific information on the discipline and is an important means of managing of educational and cognitive activity of students [0,0,0,0].

Noteworthy, lecturing for international students is rather complicated. One of the main problems is language. This is especially true for foreign students of the English medium of study. Moreover, it has been discovered that the first 20 minutes a student listens attentively to a lecture, and later can no longer concentrate so much [8,0,0].

The purpose of the paper was to elicit the features of the lecture presentation on the topic "General principles of tissue organization. Epithelial tissues" prepared for students of the English medium of study.

The lecture is the first one from the cycle "General Histology" and is intended to familiarize students in a concise and accessible form with the basic principles of human tissues structure, morphofunctional peculiarities of the epithelial tissues.

The human body is composed of four basic types of tissue: epithelial, connective, muscular, and nervous. These tissues are formed by cells and molecules of the extracellular matrix, exist not as isolated units but rather in association with one another and in variable proportions, forming different organs and systems of the body [0]. The main characteristics of these basic types of tissue are shown in **table 1**.

Epithelial tissues are composed of closely aggregated polyhedral cells with very little extracellular substance. There are two types of epithelial tissues: lining (covering) epithelia and glandular (secretory) epithelia.

The main functions of epithelial tissues are:

1. Covering, lining, and protecting surfaces (eg, skin).
2. Absorption (eg, the intestines).
3. Secretion (eg, the epithelial cells of glands).
4. Contractility (eg, myoepithelial cells).

The cells of lining (covering) epithelia have strong adhesion and form cellular sheets that cover the surface of the body and line its cavities. The epithelial tissues have some principal characteristics:

1) They are closely apposed and adhere to one another by means of specific cell-to-cell adhesion molecules that form specialized cell junctions.

2) Cells rest on a basement membrane.

3) Polarity. Cells have free and basal surfaces. Basal surface contacts the basal lamina of the basement membrane. Free surface interfaces with the external environment or spaces within the body. Because epithelial tissues face a free surface, the function of the apical surface is often very different from that at the base of the cell. This diversification is reflected by the nonhomogeneous distribution of organelles.

4) Avascular.

5) High regenerative capacity, especially in epithelial membranes, to replace continual sloughing of cells from free surface [0,0].

All epithelial cells in contact with subjacent connective tissue have at their basal surfaces a felt-like sheet of extracellular material called the basal lamina. This structure is visible only with the electron microscope, where it appears as an electron-dense layer, consisting of a network of fine fibrils, the dense layer or lamina densa. In addition, basal laminae may have electron-lucent layers on one or both sides of the dense layer, called clear layers or laminae lucida.

The term basement membrane is used to specify a periodic acid–Schiff (PAS)-positive layer, visible with the light microscope beneath epithelia. The basement membrane is formed by the combination of a basal lamina and a reticular lamina and is therefore thicker [0].

The apical surface of epithelial cells has specialized structures to increase the cell surface area or to move substances or particles bound to the epithelium: microvilli, cilia, stereocilia.

Microvilli may be short or long fingerlike extensions or folds that pursue a sinuous course, and they range in number from a few to many. Most are temporary, reflect-

Table 1.

Main characteristics of the four basic types of tissues

Tissue	Cells	Extracellular Matrix	Main Functions
Epithelial	Aggregated polyhedral cells	Small amount	Lining of surface or body cavities, glandular secretion
Connective	Several types of fixed and wandering cells	Abundant amount	Support and protection
Muscle	Elongated contractile cells	Moderate amount	Movement
Nervous	Intertwining elongated processes	None	Transmission of nervous impulses

ing cytoplasmic movements and the activity of actin filaments. In absorptive cells, such as the lining epithelium of the small intestine, the apical surface presents orderly arrays of many hundreds of more permanent microvilli. The complex of microvilli and glycocalyx is easily seen in the light microscope and is called the brush or striated border.

Stereocilia are long apical processes of cells in other absorptive epithelia such as that lining the epididymis and ductus deferens. These structures are much longer and less motile than microvilli, are branched, and should not be confused with true cilia. Like microvilli, stereocilia also increase the cells' surface area, facilitating the movement of molecules into and out of the cell.

Cilia are elongated, highly motile structures on the surface of some epithelial cells, which is much longer and two times wider than a typical microvillus. Each cilium is bounded by the cell membrane and contains an axoneme with a central pair of microtubules surrounded by nine peripheral microtubular pairs. Cilia are inserted into basal bodies, which are electron-dense structures at the apical pole just below the cell membrane. Basal bodies have a structure similar to that of centrioles [0].

Covering epithelia are tissues in which the cells are organized in layers that cover the external surface or line the cavities of the body. The traditional classification of epithelium is descriptive and based on two factors: the number of cell layers and the shape of the surface cells (**fig. 1**).

Thus, epithelium is described as:

- simple when it is one cell layer thick and
- stratified when it has two or more cell layers.

Based on cell shape, simple epithelia are classified as squamous, cuboidal and columnar:

- squamous when the width of the cell is greater than its height;
- cuboidal when the width, depth, and height are approximately the same; and
- columnar when the height of the cell appreciably exceeds the width.

One type of simple epithelium is pseudostratified columnar epithelium. So called because all cells are attached to the basal lamina even though their nuclei lie at different levels in the epithelium and the height of some cells does not extend to the surface. The best-known example of pseudostratified columnar epithelium is that lining the passages of the upper respiratory tract.

Specific names are given to epithelium in certain locations:

- endothelium is the epithelial lining of the blood and lymphatic vessels;

- endocardium is the epithelial lining of ventricles and atria of the heart;

- mesothelium is the epithelium that lines the walls and covers the contents of the closed cavities of the body (i.e., the abdominal, pericardial, and pleural cavities). Endothelium, endocardium, mesothelium are simple squamous epithelia [0].

Stratified epithelia are classified according to the cell shape of the superficial layer(s): squamous, cuboidal, columnar, and transitional.

In a stratified epithelium, the shape and height of the cells usually vary from layer to layer, but only the shape of the cells that form the surface layer is used in classifying the epithelium. For example, stratified squamous epithelium consists of more than one layer of cells, and the surface layer consists of flat or squamous cells.

The very thin surface cells of stratified squamous epithelia can be "keratinized" (rich in keratin intermediate filaments) or "nonkeratinized" (with relatively sparse amounts of keratin).

Stratified squamous keratinized epithelium is found mainly in the epidermis of skin. Its cells form many layers, and the cells closer to the underlying connective tissue are usually cuboidal or low columnar. The cells become irregular in shape and flatten as they accumulate keratin in the process of keratinization and are moved progressively closer to the surface, where they become thin, metabolically inactive packets (squames) of keratin lacking nuclei. This surface layer of cells helps protect against water loss across this epithelium.

Stratified squamous nonkeratinized epithelium lines wet cavities (eg, mouth, esophagus, and vagina). In such areas where water loss is not a problem, the flattened cells of the epithelial surface layer are living cells containing much less keratin and retaining their nuclei.

Stratified cuboidal and stratified columnar epithelia are rare. Stratified columnar epithelium can be found in the conjunctiva lining the eyelids, where it is both protective and mucus secreting. Stratified cuboidal epithelium is restricted to large excretory ducts of sweat and salivary glands, where it apparently provides a lining more robust than that of a simple epithelium.

Transitional epithelium (urothelium) is a term applied to the epithelium lining the lower urinary tract, extending from the minor calyces of the kidney down to the proximal part of the urethra. It is characterized by a superficial layer of dome-like cells that are neither squamous nor columnar. These cells, sometimes called umbrella cells, are essentially protective against the hypertonic and potentially cytotoxic effects of urine. The form of the surface cells changes according to the degree of distention of the bladder wall [0,0,0].

Glandular epithelia are formed by cells specialized to secrete. The molecules to be secreted are generally stored in the cells in small membrane-bound vesicles called secretory granules.

The epithelia that form glands can be classified according to various criteria (**fig. 2**). Unicellular glands consist of large isolated secretory cells and multicellular glands have clusters of cells. The classic unicellular gland is the gob-

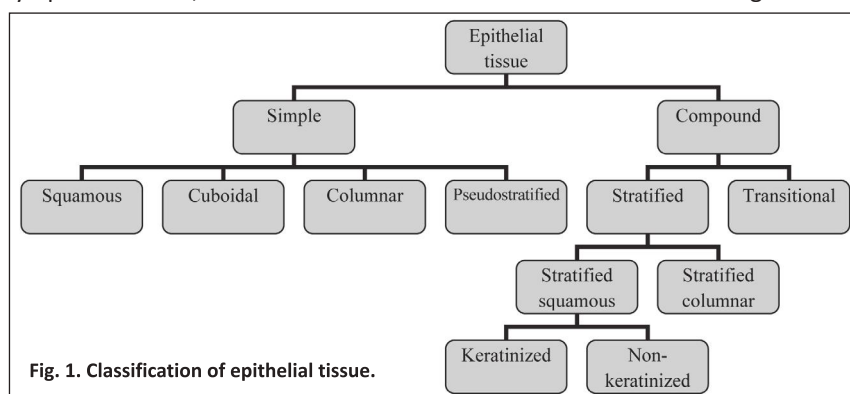
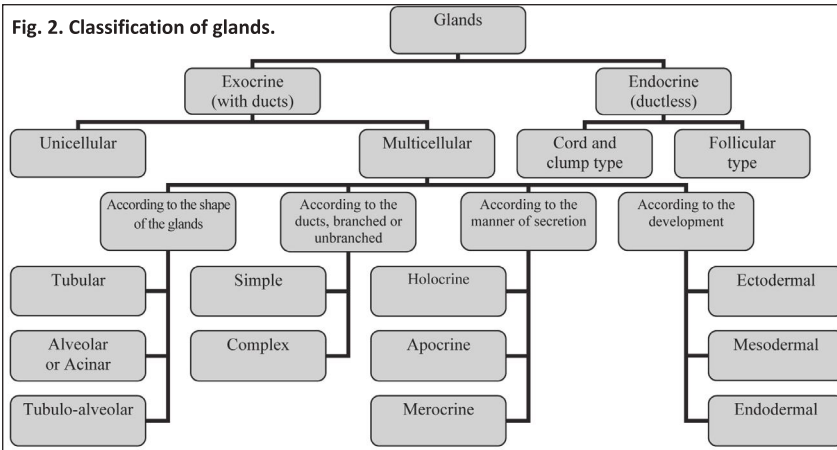


Fig. 1. Classification of epithelial tissue.



let cell in the lining of the small intestine or respiratory tract.

Glands are classified into two major groups according to how their products are released:

- exocrine glands secrete their products onto a surface directly or through epithelial ducts or tubes that are connected to a surface.
- endocrine glands lack a duct system. They secrete their products into the connective tissue, from which they enter the bloodstream to reach their target cells. The products of endocrine glands are called hormones [0].

In some epithelia, individual cells secrete substances that do not reach the bloodstream but rather affect other nearby cells. It's called paracrine signaling. The paracrine secretion has very limited signaling range; it reaches the target cells by diffusion.

In addition, many cells secrete molecules that bind to receptors on the same cell that release them. This type of own messaging is called autocrine signaling [0,0].

Cells of exocrine glands have three basic release mechanisms for secretory products:

- merocrine secretion. This secretory product is delivered in membrane-bounded vesicles to the apical surface of the cell. Here vesicles fuse with the plasma membrane and extrude their contents by exocytosis. This is the most common mechanism of secretion.
- apocrine secretion. The secretory product is released in the apical portion of the cell, surrounded by a thin layer of cytoplasm within an envelope of plasma membrane. This mechanism of secretion is found in the lactating mammary gland.
- holocrine secretion. The secretory product accumulates within the maturing cell, which simultaneously undergoes destruction orchestrated by programmed cell death pathways. Both secretory products and cell debris are discharged into the lumen of the gland. This mechanism is found in sebaceous glands of skin and the

tarsal (Meibomian) glands of the eyelid [0].

The morphology of secretory portion and ducts of the exocrine glands allows the glands to be classified according to the **table 2** and summarized as follows:

- Ducts can be simple (unbranched) or compound (branched)
- Secretory portions can be tubular (either short or long and coiled) or acinar (round or globular).
- Either type of secretory portion may be branched.
- Compound glands can have tubular, acinar, or tubuloacinar secre-

tory portions [0].

It should be noted that this lecture is accompanied by a multimedia presentation with the demonstration of photographs of micropreparations and electronograms, charts, tables, the latest video films explaining histological preparations of the epithelium of various types.

Conclusions. The lecture is an integral part of the educational process. It allows to provide students with a large amount of educational and scientific information on the discipline in a short period of time.

It is an important ways of managing the educational and cognitive activity of students for solving educational problems.

The lecture on the course "General Histology" gives important knowledge to students, which is the basis for further study of the discipline, imposes great responsibility on the teacher in preparing for the lecture.

Table 2.

Classification of exocrine glands

Classification	Typical Location	Features
Simple Glands		
Simple tubular	Large intestine: intestinal glands of the colon	Secretory portion of the gland is a straight tube formed by the secretory cells (goblet cells)
Simple coiled tubular	Skin: eccrine sweat gland	Coiled tubular structure is composed of the secretory portion located deep in the dermis
Simple branched tubular	Stomach: mucus-secreting glands of the pylorus Uterus: endometrial glands	Branched tubular glands with wide secretory portion are formed by the secretory cells and produce a viscous mucous secretion
Simple acinar	Urethra: paraurethral and periurethral glands	Simple acinar glands develop as an outpouching of the transitional epithelium and are formed by a single layer of secretory cells
Branched acinar	Stomach: mucus-secreting glands of cardia Skin: sebaceous glands	Branched acinar glands with secretory portions are formed by mucussecreting cells; the short, single-duct portion opens directly into the lumen
Compound Glands		
Compound tubular	Duodenum: submucosal glands of Brunner	Compound tubular glands with coiled secretory portions are located deep in the submucosa of the duodenum
Compound acinar	Pancreas: exocrine portion	Compound acinar glands with alveolarshaped secretory units are formed by pyramid-shaped serous-secreting cells
Compound tubuloacinar	Submandibular salivary gland	Compound tubuloacinar glands can have both mucous branched tubular and serous branched acinar secretory units; they have serous end-caps (demilunes)

References

1. Hryshchuk MI. Naukovo-metodychni osnovy vykladannia fundamentalnykh dystsyplyn inozemnym studentam-medykam. Medical education. 2012;3:27-9. [in Ukrainian].
2. Pro vyshchu osvitu: Zakon Ukrainy vid 01.07.2014 r. № 1556-VII VR. [in Ukrainian].
3. Maksymenko SD, Filonenko MM. Pedahohika vyshchoi medychnoi osvity. Kyiv: Tsentri uchbovoi literatury; 2014. 288 s. [in Ukrainian].
4. Khripkov IS. Metodychni pidkhody do vykladannia rozdlu «Peryferychni endokrynni zalozy» v lektsiinomu kursi ta na praktychnykh zaniattiakh z histologii. Morphologia. 2017;11(4):80-4. [in Ukrainian].
5. Denevil OV, Saturska HS, Potikha NYa. Innovatsiini metody pidkhodu do optymizatsii chytannia lektsii z patolohichnoi fiziologii. Medical education. 2013;3:45-7. [in Ukrainian].
6. Cherkasov VH, Ostapuyuk LI, Dzevulska IV, Kovalchuk OI. Anatomichna lektsiia yak vazhlyvyi zasib formuvannia korporatyvnoi akademichnoi kultury. Medical education. 2015;3:90-3. [in Ukrainian].
7. Shepitko VI, Yakushko OS, Lysachenko OD, Yeroshenko GA, Yeryomina NF, Boruta NV. Dosvid vykorystannia informatsiinykh tekhnologii na kafedri histologii, tsytologii ta embriologii. Zhdan VM, redaktor. Materialy nauk.-prakt. konf. z mizhnar. uchastiu. Aktualni pytannia kontroliu yakosti osvity u vyshchykh navchalnykh zakladakh; 2018 Mar. 22; Poltava; 2018. s. 248-50. [in Ukrainian].
8. Shepitko VI, Yakushko OS, Yeroshenko GA, Lysachenko OD. Shliakhy udoskonalennia metodyky vykladannia histologii, tsytologii ta embriologii inozemnym studentam anhliskoiu movoiu. World of Medicine and Biology. 2012;4:132-3. [in Ukrainian].
9. Knyazevych-Chorna TV. Osoblyva rol lektsii pry vykladanni teoretychnykh dystsyplyn studentam-inozemtsiam u vyshchykh medychnykh zakladakh. Galician Medical Journal. 2013;20(1):104-5. [in Ukrainian].
10. Iakushko OS. The modern concept of morphological and functional features of the endocrine glands. World of Medicine and Biology. 2016;4(58):153-9.
11. Gartner LP, Hiatt JL. Color atlas and text of histology. Philadelphia: Wolters Kluwer Health; 2014. 525 p.
12. Junqueira LC, Mescher AL. Junqueira's Basic Histology: text and atlas. 12th ed. New York: McGraw-Hill Medical; 2010. 467 p.
13. Ross MH, Pawlina W. Histology: a text and atlas: with correlated cell and molecular biology. 17th ed. Philadelphia: Wolters Kluwer Health; 2016. 984 p.
14. Vasudeva N, Mishra S. Textbook of human histology with colour atlas and practical guide. New Delhi: Jaypee Brothers Medical Publishers; 2014. 440 p.
15. Eroschenko VP. Atlas of Histology with functional correlations. Philadelphia: Wolters Kluwer Health; 2017. 617 p.

ГІСТОФУНКЦІОНАЛЬНІ ОСОБЛИВОСТІ ЕПІТЕЛІАЛЬНИХ ТКАНИН

Якушко О. С.

Резюме. В умовах підвищеного попиту іноземних громадян щодо отримання медичної освіти в Україні доцільним є створення ефективних прогресивних методів навчання і контролю знань студентів. Пріоритетна роль у передачі інформації належить лекції, яка є важливим засобом керування навчально-пізнавальною діяльністю студентів. Вона дає можливість за короткий проміжок часу надати значний обсяг матеріалу, ознайомити з передовими технологіями, зануритись у предмет, що вивчається, з метою забезпечення оптимальних умов для підвищення мотивації студентів. Досить складним є читання лекцій іноземним громадянам, що потребує з боку викладача не тільки глибоких знань з власної дисципліни, а й з педагогіки, психології, етики. Лекції з курсу «Загальна гістологія» ознайомлюють студентів з морфофункціональними особливостями тканин людського організму. Лекційний матеріал з теми «Епітеліальні тканини» адаптований до сучасних вимог навчального процесу, містить відеофільми, велику кількість малюнків, фотографій мікропрепаратів, що викликає зацікавленість у студентів, полегшує сприйняття, закладає підґрунтя для подальшого вивчення гістології.

Ключові слова: лекція, гістологія, епітеліальні тканини.

ГИСТОФУНКЦИОНАЛЬНЫЕ ОСОБЕННОСТИ ЭПИТЕЛИАЛЬНЫХ ТКАНЕЙ

Якушко Е. С.

Резюме. В условиях повышенного спроса иностранных граждан на получение медицинского образования в Украине целесообразным является создание эффективных прогрессивных методов обучения и контроля знаний студентов. Приоритетная роль в передаче информации принадлежит лекции, которая является важным средством управления учебно-познавательной деятельностью студентов. Она дает возможность за короткий промежуток времени предоставить значительный объем материала, ознакомит с передовыми технологиями, погрузиться в изучаемый предмет с целью обеспечения оптимальных условий для повышения мотивации студентов. Достаточно сложным является чтение лекций иностранным гражданам, что требует со стороны преподавателя не только глубоких знаний своей дисциплины, но и педагогики, психологии, этики. Лекции из курса «Общая гистология» знакомят студентов с морфофункциональными особенностями тканей человеческого организма. Лекционный материал по теме «Эпителиальные ткани» адаптирован к современным требованиям учебного процесса, содержит видеофильмы, большое количество рисунков, фотографий микропрепаратов, что вызывает живой интерес у студентов, облегчает восприятие, закладывает почву для дальнейшего изучения гистологии.

Ключевые слова: лекция, гистология, эпителиальные ткани.

HISTOPHYSIOLOGICAL FEATURES OF EPITHELIAL TISSUES

Yakushko O. S.

Abstract. The competitiveness of the national system of medical education in the world market of educational services is evidenced by the quality of training of international students, especially the English-language form of instruction. In the conditions of increased demand of foreign citizens for medical education in Ukraine, the provision of optimal conditions and effective progressive methods of teaching and students' knowledge control is rational. The lecture is distinguished by its time effectiveness, the ability to accumulate and provide students with a large amount

of academic and scientific information on the discipline and is an important means of managing of educational and cognitive activity of students. Lecturing for international students is rather complicated. It requires from the teacher not only a deep knowledge of his discipline, but also pedagogy, psychology, ethics. Lectures from the cycle "General Histology" introduce students to the morphofunctional features of the tissues of the human body. The lecture material from the topic "Epithelial tissues" is adapted to the modern requirements of the educational process, contains a large number of drawings, photographs of micro-preparations, video films. It causes a lively interest among students, facilitates perception, lays the ground for further studying histology. Epithelium is an avascular tissue composed of cells that cover the exterior body surfaces and line internal closed cavities. Epithelium also forms the secretory portion of glands and their ducts. Specialized epithelial cells function as receptors for the special senses (smell, taste, hearing, and vision). Epithelial tissues are composed of closely aggregated polyhedral cells with very little extracellular substance. Covering epithelia has cells which are organized in layers that cover the external surface or line the cavities of the body. This type of epithelial tissues are classified to the simple (contain only one layer of cells) and stratified (contain more than one layer). Glandular epithelia are formed by cells specialized to secrete. Glands are classified into two major groups according to how their products are released: exocrine and endocrine. The morphology of secretory portion and ducts of the exocrine glands allows the glands to be classified to simple and compound.

Key words: lecture, histology, epithelial tissue.

*Рецензент – проф. Єрошенко Г. А.
Стаття надійшла 04.01.2019 року*

DOI 10.29254/2077-4214-2019-1-1-148-221-224

УДК 378.14:616.31:614.253.4

Янко Н. В.

СПРИЙНЯТТЯ ФАХОВИХ КОМПЕТЕНТНОСТЕЙ З ПРОФІЛАКТИКИ СТОМАТОЛОГІЧНИХ ЗАХВОРЮВАНЬ СЕРЕД СТУДЕНТІВ 4 КУРСУ СТОМАТОЛОГІЧНОГО ФАКУЛЬТЕТУ УКРАЇНСЬКОЇ МЕДИЧНОЇ СТОМАТОЛОГІЧНОЇ АКАДЕМІЇ Українська медична стоматологічна академія (м. Полтава)

latned@ukr.net

Вступ. Вперше в стоматологічній освіті концепція навчального плану, орієнтованого на компетентності, була запропонована 25 років тому у США Chambers D.W. [1], який описав їх як навички, що поєднують знання та професійні погляди і здійснюються самостійно. В Європейській Спільноті компетентності для випускників-стоматологів були узагальнені організацією Dent Ed Thematic Network у 2005 році та перезатверджені Association for Dental Education in Europe (ADEE) в 2009 році [2]. Україна долучилася до цього процесу весною 2016 року, коли почалась розробка нових стандартів вищої освіти, які містять переліки компетентностей випускників та результатів навчання.

На третьому році навчання студенти вивчають навчальну дисципліну «Профілактика стоматологічних захворювань» та проходять виробничу лікарську практику з профілактики стоматологічних захворювань. Робочі програми цих дисциплін на 2018/2019 навчальний рік створені згідно навчального плану підготовки кваліфікації освітньої «Магістр стоматології», кваліфікації лікарської «Лікар стоматолог» (Київ, 2016) та містять інтегральну, загальні та спеціальні (фахові) компетентності; у попередні роки програми містили лише результати навчання, які відповідають компетентностям.

Декілька недавніх досліджень продемонстрували сприйняття клінічних компетентностей із профілактичної стоматології студентами-випускниками [3,4] або студентами 3-5 курсів [5,6]. В Україні подібних досліджень ще не проводилось.

Метою дослідження був аналіз самооцінки фахових компетентностей студентами четвертого курсу,

які вивчали на третьому курсі профілактику стоматологічних захворювань.

Об'єкт і методи дослідження. Для аналізу було вибрано 10 фахових (спеціальних) компетентностей із навчальної дисципліни «Профілактика стоматологічних захворювань»:

K1 – провести стоматологічне обстеження дитини із визначенням індексів карієсу, гігієнічних та пародонтальних індексів;

K2 – виявляти карієсогенну ситуацію в порожнині рота;

K3 – рекомендувати методи, засоби та предмети гігієни порожнини рота у залежності від стоматологічного статусу;

K4 – проводити контрольоване чищення зубів у дітей та професійну гігієну порожнини рота;

K5 – проводити навчання методам гігієни порожнини рота;

K6 – використовувати різні форми та методи санітарно-просвітницької роботи для гігієнічного навчання;

K7 – планувати та рекомендувати засоби ендогенної профілактики карієсу зубів для дітей різного віку;

K8 – проводити ремінералізуючу терапію;

K9 – проводити герметизацію фісур;

K10 – планувати заходи профілактики захворювань пародонта у дітей різного віку.

У робочій програмі навчальної дисципліни «Виробничу лікарську практику» ці компетентності узагальнені та відповідають результатам навчання для першого модуля «Виробничу лікарську практику з профілактики стоматологічних захворювань».